

**PATIENT**

Max Mins-Tchoungjo

SPECIES

Feline

BREED

DSH

SEX

Male Neutered

AGE

2.9.15

WEIGHT

13.7lbs

INTERPRETED BYMaggie Machen Lamy,
DVM, DACVIM
(Cardiology)**HOSPITAL NAME**

Banfield Towson

REFERRING VET

Dr. Washington

INVOICE

32327

DATE

8.11.23

PRESENTING CLINICAL SIGNS

History: Recheck echo. Persistent heart murmur. Arrhythmia.

-Current medications: Atenolol 25mg/mL: 0.25ml q24h

-Sedation used: 300mg Gabapentin.

-Pertinent previous ultrasound results (11/29/22 MML): VPCs (singles and a couplet. Asymmetric hypertrophy (0.58/1.0cm, mild LAE (1.4).

-STAT: Declined at this time.

-Imaging performed by: Stephanie Warga RDCS, RVT.

ELECTROCARDIOGRAPHIC FINDINGS

A six lead ECG is available at 25mm/s; 5mm/mV. The average heart rate is 155bpm with a largely regular rhythm (brief tachycardia, up to 180bpm). The rhythm is sinus in origin, with a p for every QRS complex and vice versa. The P wave morphology is positive with a normal dimension. Normal PR. The QRS morphology is positive with normal dimension with a notched appearance. MEA is normal. No ectopic beats, pauses or dysrhythmias observed.

ECG diagnosis: Normal sinus rhythm with apparently controlled VPCs.

ECHOCARDIOGRAM FINDINGS

2D, m-mode, color flow and doppler imaging is available. The left ventricular wall is asymmetric with minimally septal thickening and a markedly thickened free wall. There is a diffusely hyperechoic endocardium consistent with fibrosis. The papillary muscles are mildly hypertrophied and hyperechoic. The endocardium also appears remodeled. The left atrium is mildly enlarged. The right atrium is normal in size. The right ventricle appears normal. The mitral valve is normal in structure and mobility. No MR. Blood flow through both the LVOT and RVOT is normal in velocity. No pleural or pericardial effusion seen. No obvious cardiac tumors.

CARDIAC CHART -

FELINE CARDIAC PARAMETERS	BODY WEIGHT (kg)	HR (BPM)	IVSd (cm) <small>(Moise, Pipers)</small>	LVIDd (cm) <small>(Moise, Pipers)</small>	LWVd (cm) <small>(Moise, Pipers)</small>	FS (%)	EF (%)
NORMAL PARAMETER	-----	150-240	3.5-0.55	<2 (mean 1.5)	3.5-0.55	35-67	80-100
PATIENT	6.2	NM	0.47	1.7	0.97	47	80
FELINE CARDIAC PARAMETERS	LA/AO (Boon)	LA/AO HEART BASE (Swe) (Abbott)	LA 2D short axis Base view (cm) (Abbott)		LVOT VEL (m/s)	RVOT VEL (m/s)	E max (m/s)
NORMAL	<1.5	<1.3	<1.2		<1.6	<1.3	<0.9
PATIENT	NM	1.4	1.6		0.84	1.0	NM

Adapted from June Boon, Veterinary Echocardiography, 1998
 Abbott J & MacLean H JVIM 2006;20: 111-119, Moise et al. Am J Vet Res 47:1476, 1986. Pipers et al. Am J Vet Res 40:882, 1979.

INTERPRETATION OF THE FINDINGS & FURTHER RECOMMENDATIONS

Persistent significant yet stable disease is identified in this study. The LV remains highly asymmetric with marked free wall hypertrophy. The LA is slightly increased comparatively; however, remains mild overall. No additional structural issues are identified.

The good news is the ECG does show adequate control of both heart rate and ventricular beats with none identified. No additional medications are warranted at this time; however, routine blood pressure monitoring is recommended.

Prognosis remains guarded, although stability is certainly a good sign. Patient will always be at risk for progression to CHF, malignant blood clot events and/or sudden death going forward.

Monitor at home for any respiratory issues or signs of blood clot events (neurologic change, paralysis, etc.).

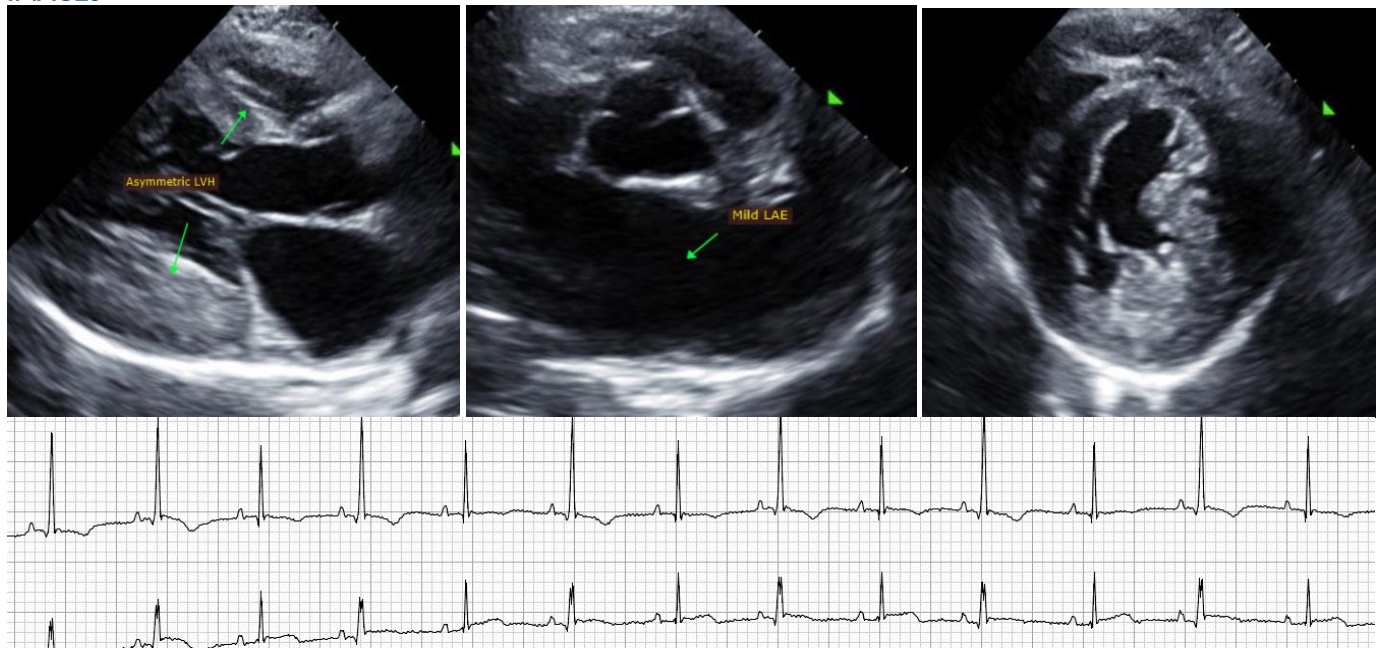
Elective anesthesia is not advised.

PLAN

Screening BP and T4 are recommended. Continue Atenolol as prescribed.

A recheck echocardiogram is recommended in 6 months to assess for progression, sooner if any clinical signs develop in the interim.

IMAGES



The information and recommendations provided are based on the images presented by the referring veterinarian. No evaluation can be communicated regarding pathology that was not visible in the image/video clips provided.

Thank you for this referral. This report was generated using transcription software, and minor dictation errors may be present. If the clinical or image interpretation does not parallel your findings or if I can be of any further assistance, please contact me.

Maggie Machen Lamy, DVM
Diplomate of the American College of Veterinary Internal Medicine (Cardiology)
info@sonopath.com